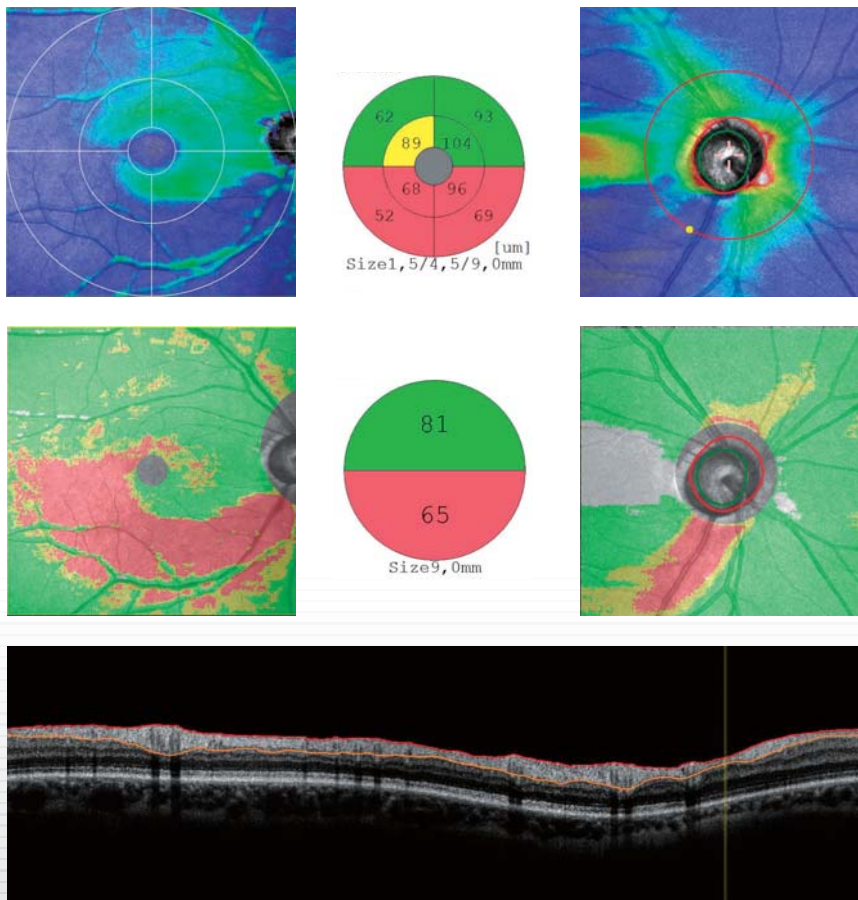


# GLAUCOMA

## Clinical Data Book



Dr. Heike Krueger  
Dr. Cesary J. Krueger



# CONTENTS

<b><i>Introduction - Glaucoma Analysis</i></b>	<b>2</b>
<b><i>Stages of Glaucoma</i></b>	<b>4</b>
<b><i>Cases</i></b>	
<b>26-year-old female</b>	<b>6</b>
Right eye	- Normal eye, BCVA 20/20
Left eye	- Normal eye, BCVA 20/20
<b>72-year-old female</b>	<b>8</b>
Right eye	- Preperimetric Glaucoma, BCVA 16/20
Left eye	- Preperimetric Glaucoma, BCVA 16/20
<b>49-year-old female</b>	<b>10</b>
Right eye	- Glaucoma Aulhorn stage 1, BCVA 20/20
Left eye	- Glaucoma Aulhorn stage 1, BCVA 20/20
<b>62-year-old male</b>	<b>12</b>
Right eye	- Glaucoma Aulhorn stage 2, BCVA 20/20
Left eye	- Glaucoma Aulhorn stage 1, BCVA 20/20
<b>67-year-old female</b>	<b>14</b>
Right eye	- Glaucoma Aulhorn stage 3, BCVA 16/20
Left eye	- Glaucoma Aulhorn stage 4, BCVA 20/20
<b>74-year-old male</b>	<b>16</b>
Right eye	- Glaucoma Aulhorn stage 4, BCVA 16/20
Left eye	- Glaucoma Aulhorn stage 5, BCVA 16/20
<b>68-year-old female</b>	<b>18</b>
Right eye	- Glaucoma Aulhorn stage 5, BCVA 6/20
Left eye	- Glaucoma Aulhorn stage 1, BCVA 12/20
<b><i>Authors</i></b>	<b>20</b>

# Introduction - Glaucoma Analysis

NAVIS-EX (ver. 1.3.3)

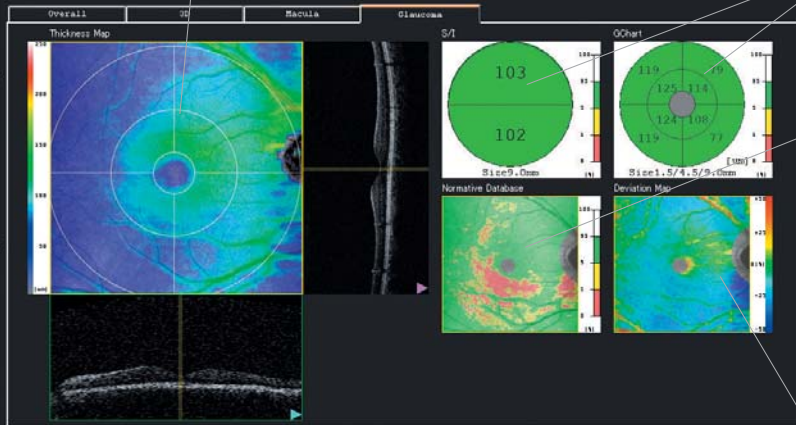
## >> [NFL+GCL+IPL] thickness map

### [NFL+GCL+IPL] thickness map

Color-coded thickness map (9 mm x 9 mm) of [NFL+GCL+IPL] layers (ILM to IPL / INL) overlaid on SLO image

### Analysis charts (Superior / Inferior pole, GChart)

Analysis charts of average thickness of each sector surrounding the macula with color code based on comparison to a normative database



### Normative database

Color-coded map indicating distribution range of the patient's [NFL+GCL+IPL] thickness in a population of normative eyes

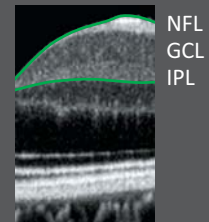
- More than 95%
- More than 5 to 95%
- More than 1 to 5%
- 0 to 1%

### Deviation map

Map indicating the deviation, including early variation even within normal range, from average thickness in a normative database

### What the [NFL+GCL+IPL] are.

The [NFL+GCL+IPL] are layers composed of Nerve Fiber Layer (NFL), Ganglion Cell Layer (GCL), and Inner Plexiform Layer (IPL). The [NFL+GCL+IPL] thickness map shows objective status in region of nerve fiber layer defect and visual field abnormality caused by glaucoma.



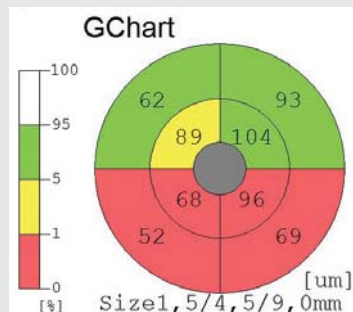
## >> Retinal Pathology or Glaucoma?

### Glaucoma Screening with Normative DB

Thicker NFL+GCL+IPL thickness than normal

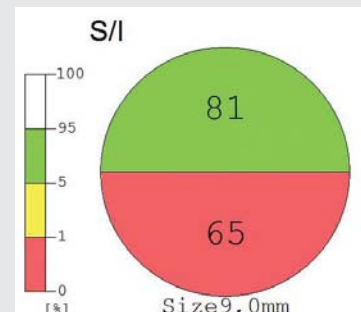
Normal NFL+GCL+IPL thickness

Thinner NFL+GCL+IPL thickness than normal (Glaucoma Suspect)



Temporal region is normal [NFL+GCL+IPL] thickness.

Inferior region has thinner [NFL+GCL+IPL] thickness than normal thickness.



## >> RNFL thickness map

**SLO image**  
SLO image showing optic disc

**RNFL thickness map**  
Color-coded thickness map of RNFL layer (ILM to NFL / GCL)

**Normative database**  
Color-coded map indicating distribution range of the patient's RNFL thickness in a population of normative eyes

**Analysis charts**  
Analysis charts indicating average thickness with color code based on comparison to a normative database:

- Whole
- S / I (2-sector)
- TSNIT (4-sector)
- Clock Hour (12-sector)

**Analysis table**  
Table of optic disc analysis:

- C / D ratio (horizontal)
- C / D ratio (vertical)
- R / D ratio (minimum)
- R / D ratio (angle)
- Disc area (mm<sup>2</sup>)
- Cup area (mm<sup>2</sup>)

**TSNIT graph**  
Graph showing thickness from ILM to NFL / GCL on disc circle with comparison to a normative database

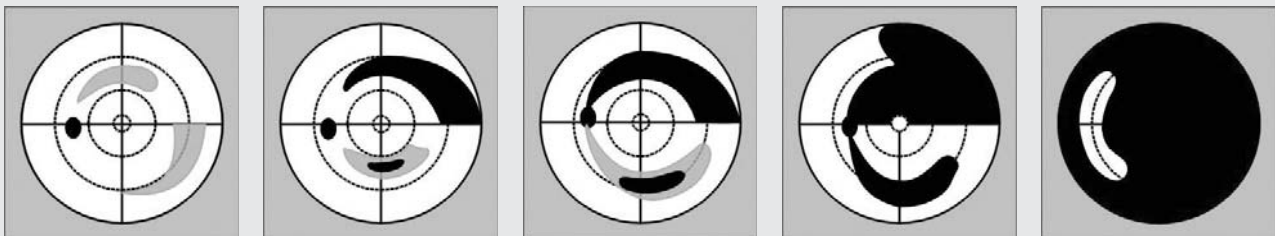
**TSNIT analysis**

Graph shows RNFL thickness on disc circle with comparison to a normative database. Table of each RNFL thickness with color code based on normative database:

- Overall average
- Superior pole average
- Inferior pole average

## >> Aulhorn classification of visual field

Classification of glaucoma based upon static visual field with Twinfield-Perimeter (OCULUS Optikgeraete GmbH, Germany)



Stage 1

Stage 2


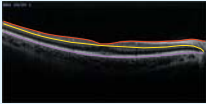
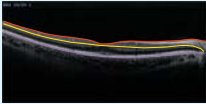
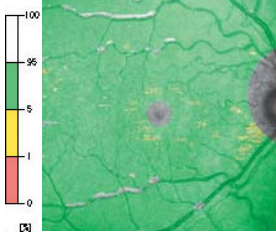
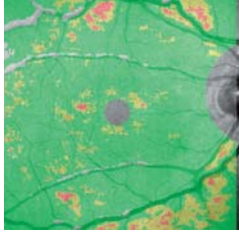
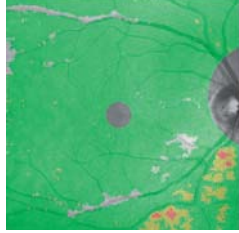
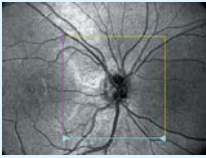


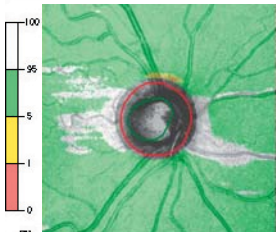
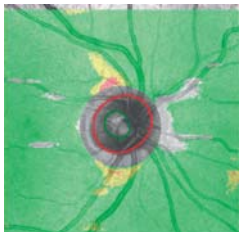
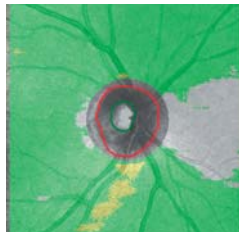



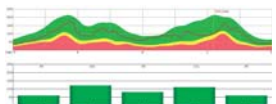
Stage 3

Stage 4

Stage 5

Stage 1	Relative scotomas only
Stage 2	Absolute scotomas, without connection to the blind spot
Stage 3	Absolute scotomas, with connection to the blind spot
Stage 4	Absolute scotomas, more than one quadrant affected
Stage 5	Temporal residual visual field only

# Stages of Glaucoma

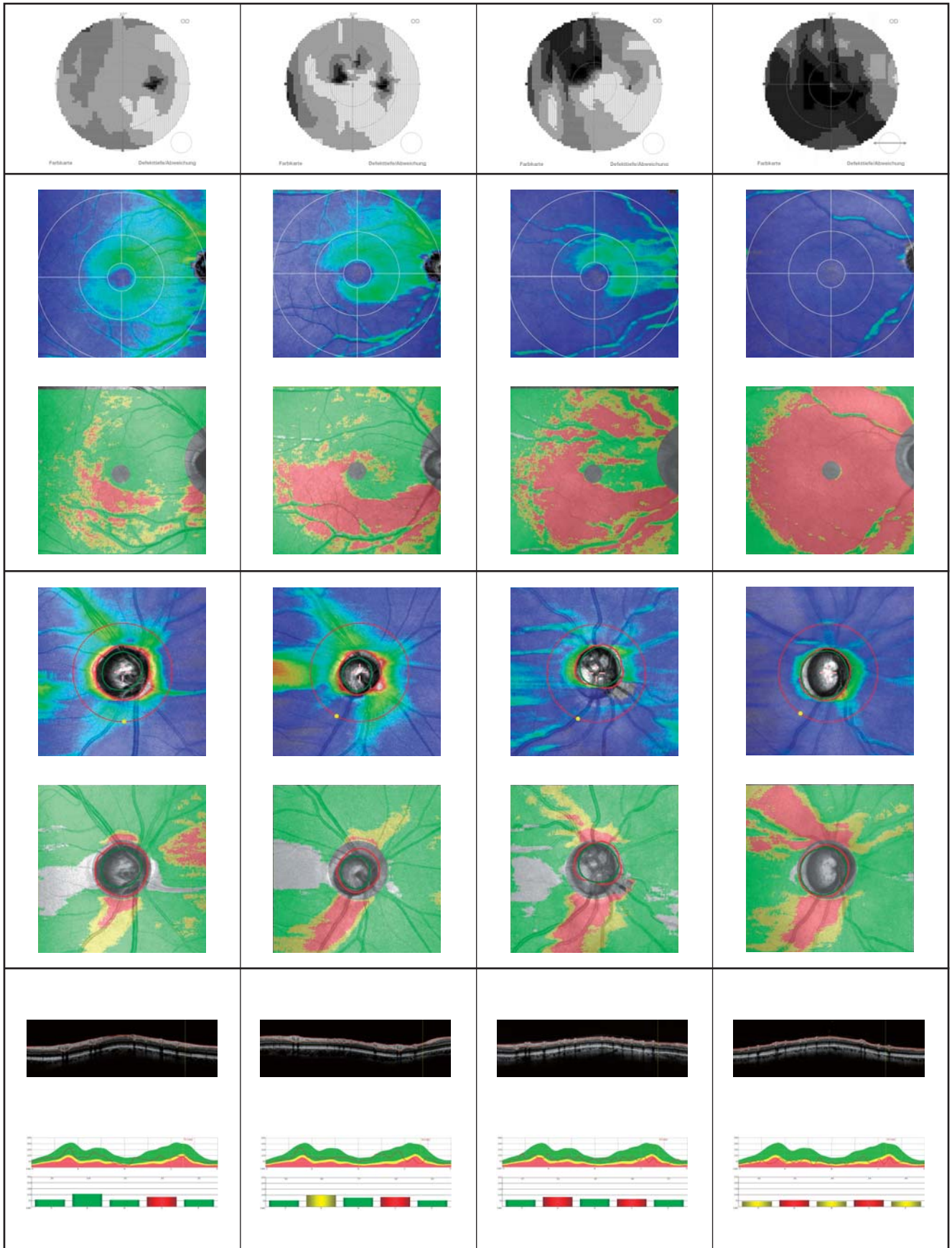
		Normal	Preperimetric	Aulhorn 1
<b>Visual Field</b>				
<b>[NFL+GCL+IPL]</b>	Thickness Map			
	Normative Database			
				
<b>RNFL</b>	Thickness Map			
	Normative Database			
				
<b>TSNIT graph</b>	B-Scan			
	Graph			

**Aulhorn 2**

**Aulhorn 3**

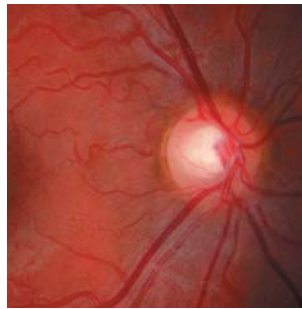
**Aulhorn 4**

**Aulhorn 5**

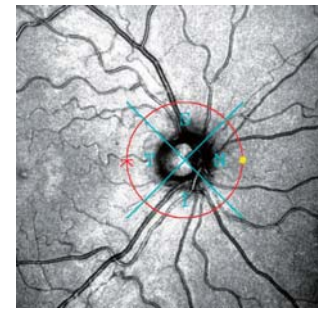


No glaucoma present,  
excavation of optic nerve head,  
normal intraocular pressure,  
normal visual field

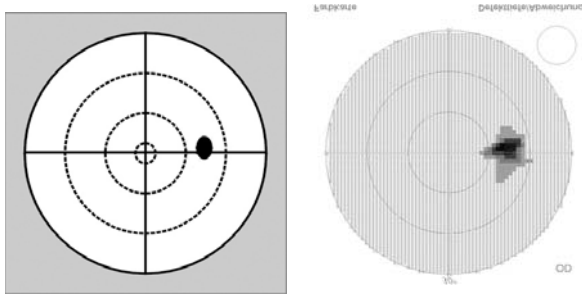
Fundus Photo



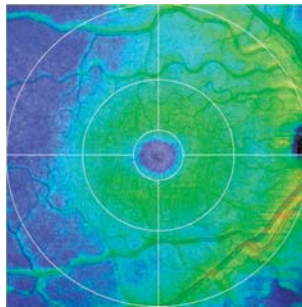
SLO



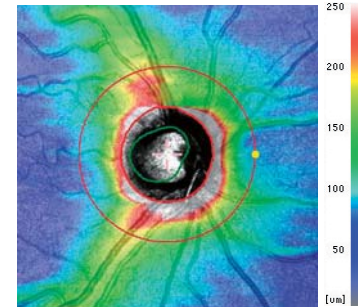
Perimeter  
Mirrored representation



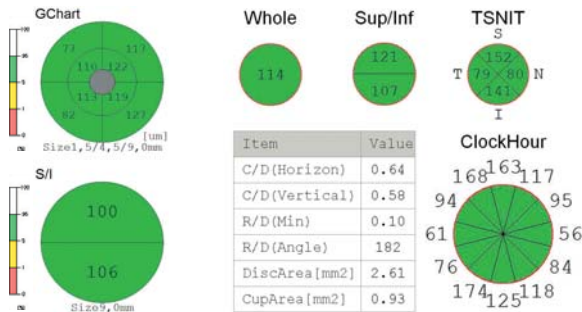
[NFL+GCL+IPL]  
thickness map



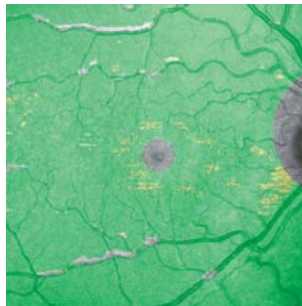
RNFL  
thickness map



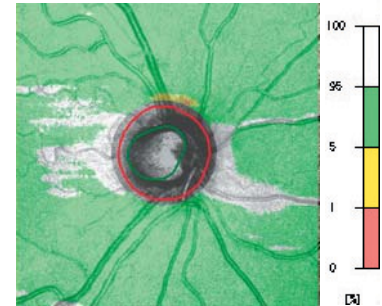
Analysis charts



NDB/ [NFL+GCL+IPL]  
thickness map

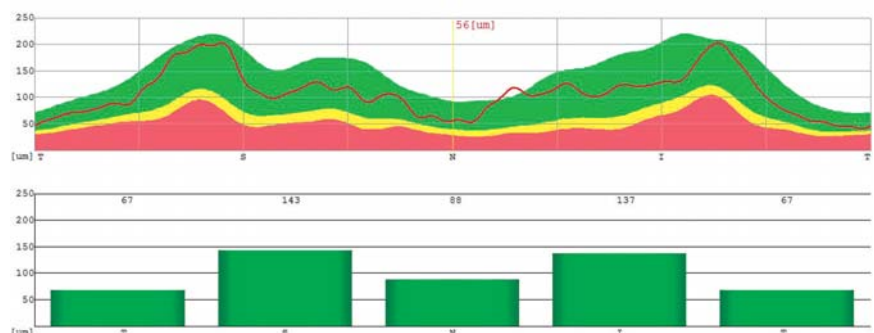
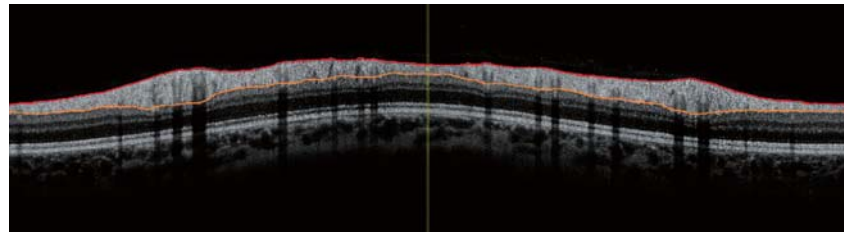


NDB/ RNFL  
thickness map



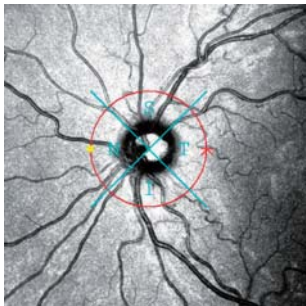
No evident abnormalities

TSNIT Graph

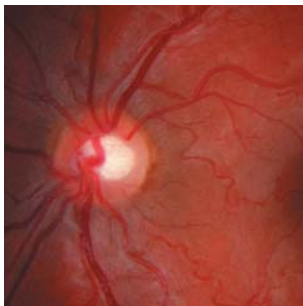




SLO

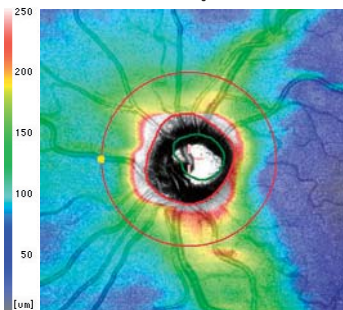


Fundus Photo

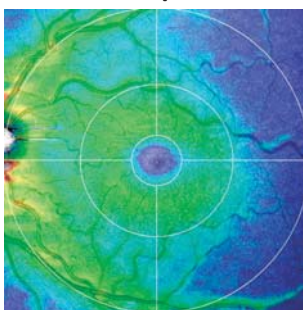


Same patient as a patient on the previous page

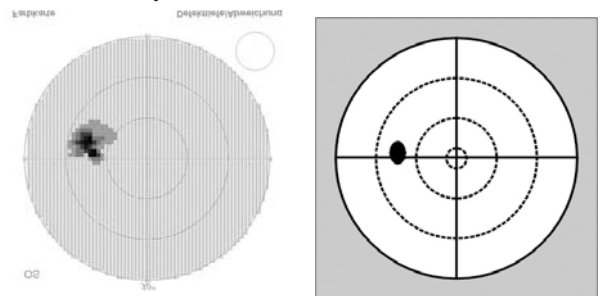
RNFL thickness map



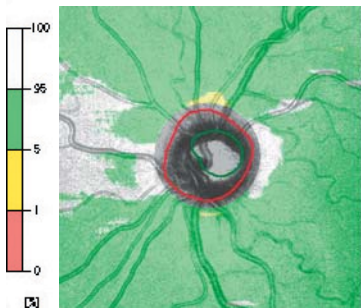
[NFL+GCL+IPL] thickness map



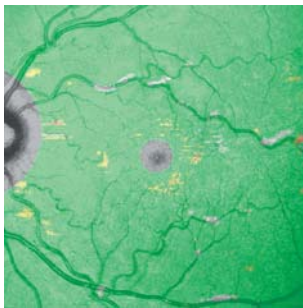
Perimeter Mirrored representation



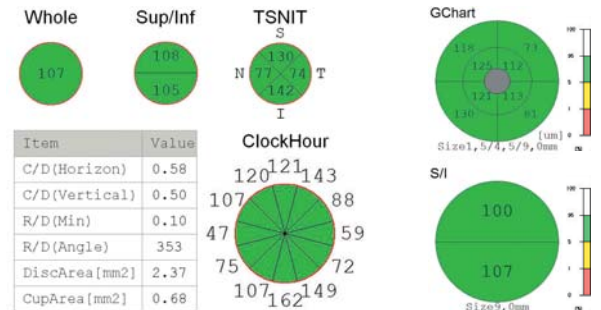
NDB/ RNFL thickness map



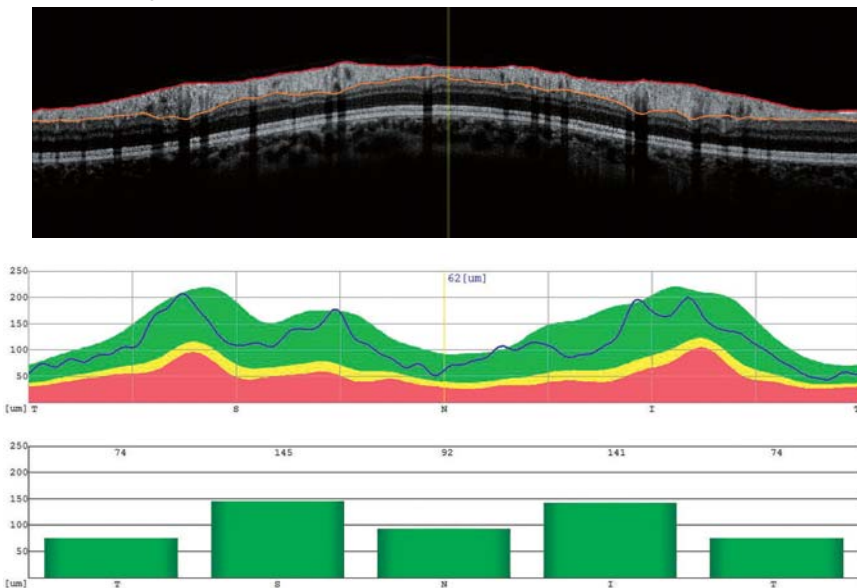
NDB/ [NFL+GCL+IPL] thickness map



Analysis charts

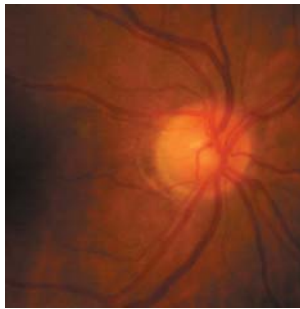


TSNIT Graph

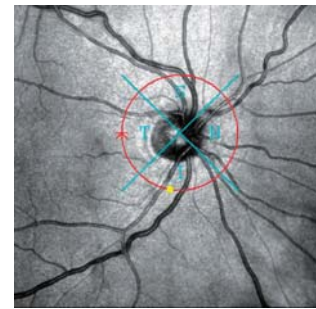


Ocular hypertension, due to intraocular pressure over 26 mmHg and thin cornea (510/530 μm) in therapy with anti-glaucoma drops since the age of 55, normal visual field

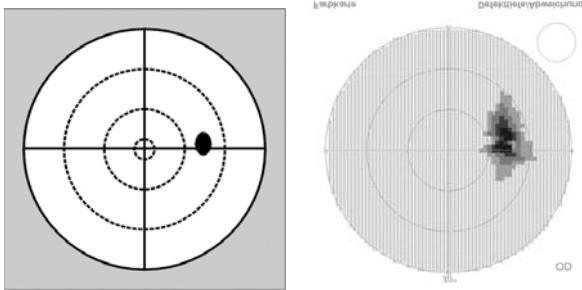
Fundus Photo



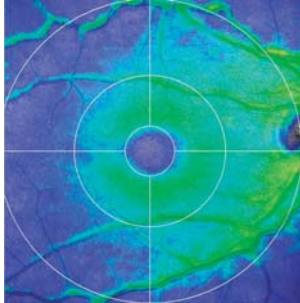
SLO



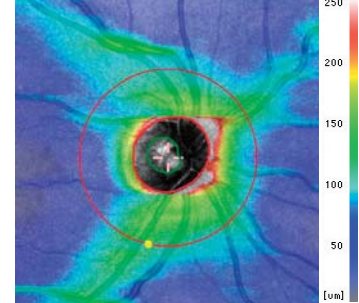
Perimeter  
Mirrored representation



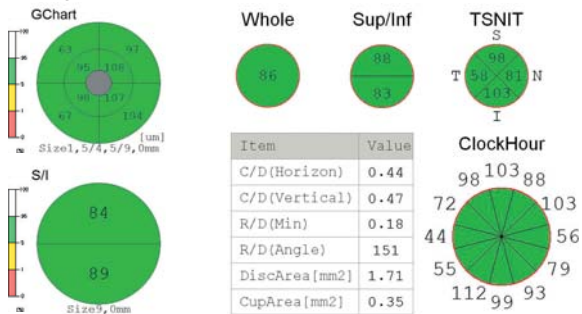
[NFL+GCL+IPL]  
thickness map



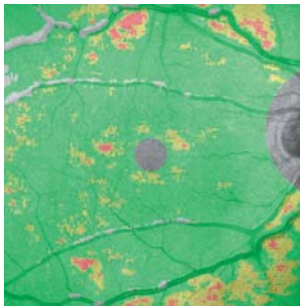
RNFL  
thickness map



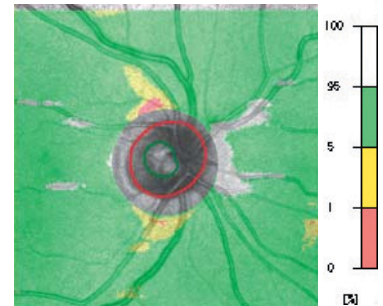
Analysis charts



NDB/ [NFL+GCL+IPL]  
thickness map



NDB/ RNFL  
thickness map

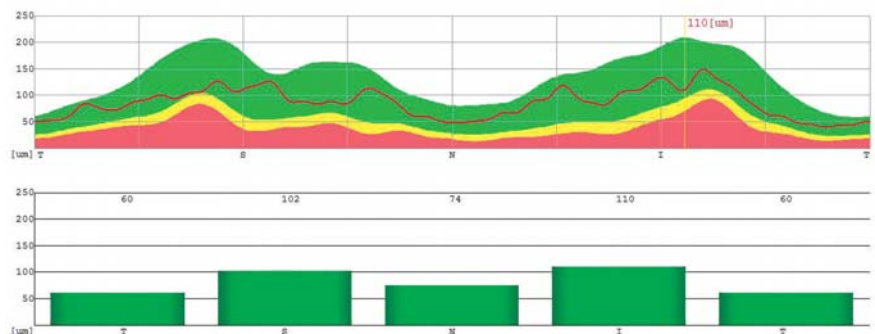
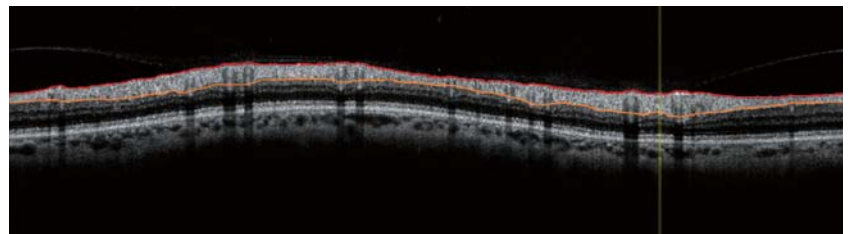


With normal mean values in the **Analysis charts**:  
The **NDB/[NFL+GCL+IPL] thickness map** shows spots of thinner locations, especially in the lower area.

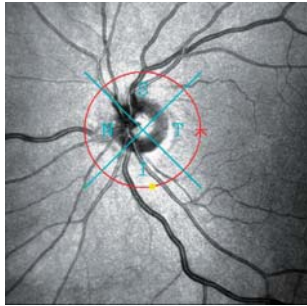
The **NDB/ RNFL thickness map** shows mild thinning of nerve fiber layers downwards.

The **TSNIT graph** shows thinning in the inferior quadrants.

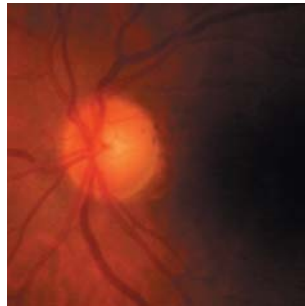TSNIT Graph



SLO

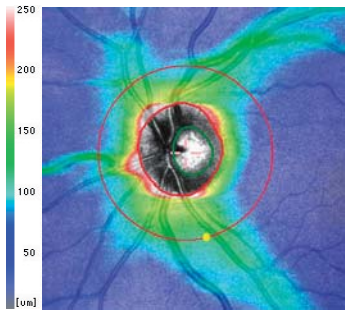


Fundus Photo

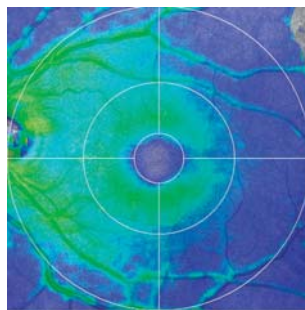


Same patient, visual field of left eye with not constantly ascertainable relative scotomas in the upper temporal area

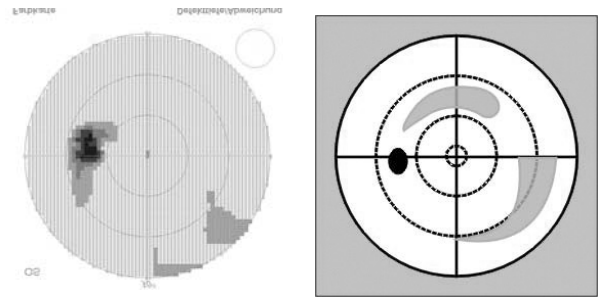
RNFL thickness map



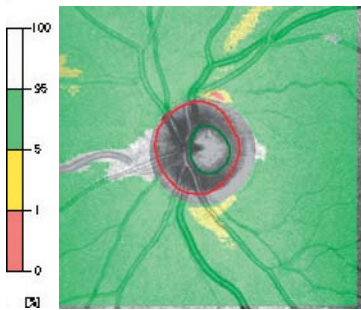
[NFL+GCL+IPL] thickness map



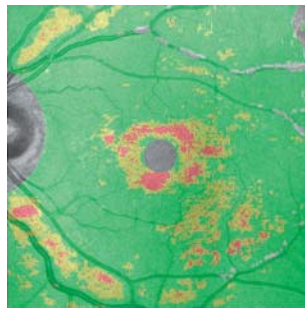
Perimeter Mirrored representation



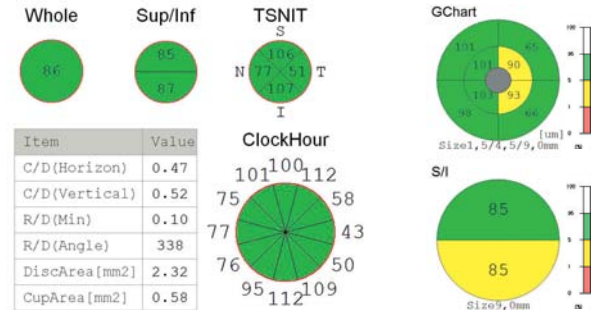
NDB/ RNFL thickness map



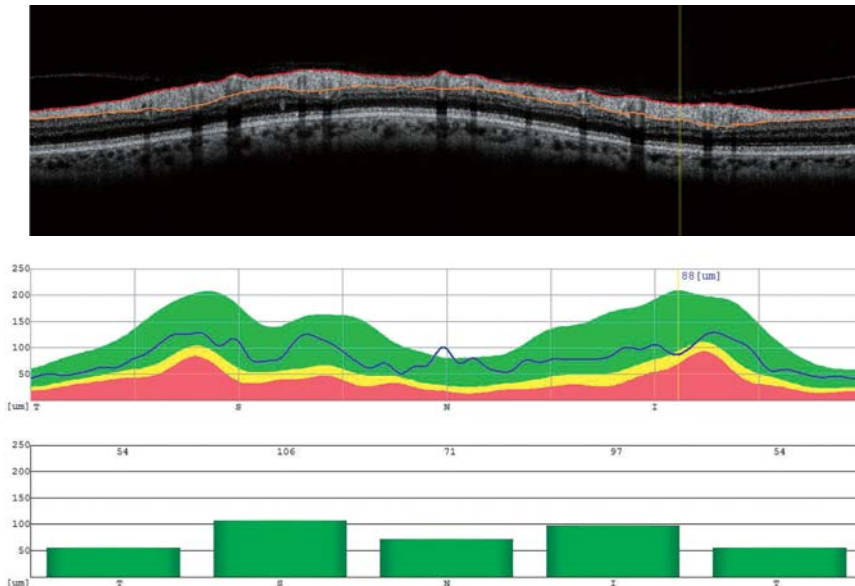
NDB/ [NFL+GCL+IPL] thickness map



Analysis charts



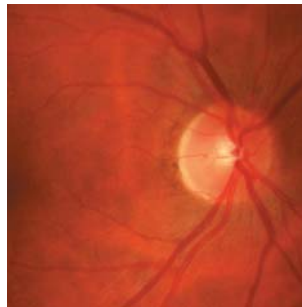
TSNIT Graph



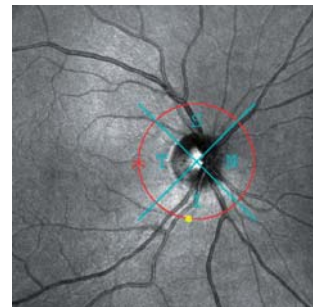
Similar findings as in the right eye, but the macular Analysis charts show evident average values.

Primary open angle glaucoma, POAG, tension regulated with medication, visual fields with persistent relative scotomas in the areas of nerve fiber bundles

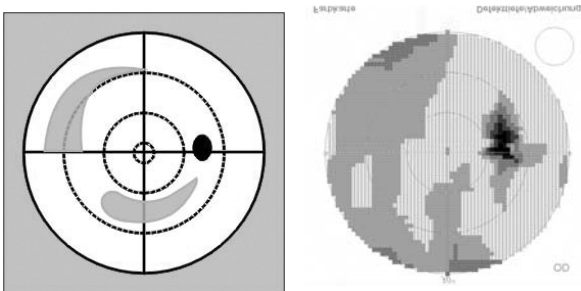
Fundus Photo



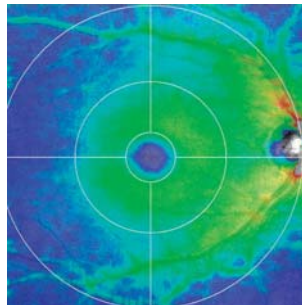
SLO



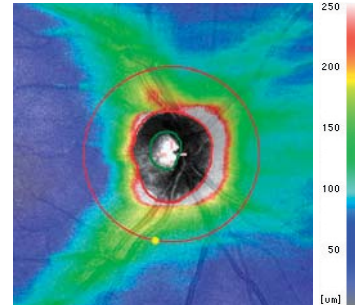
Perimeter  
Mirrored representation



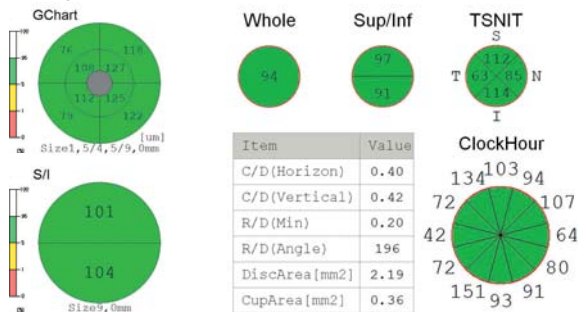
[NFL+GCL+IPL]  
thickness map



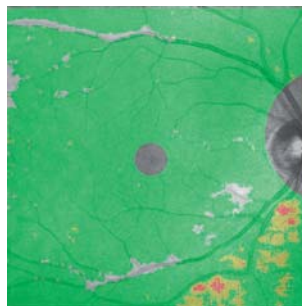
RNFL  
thickness map



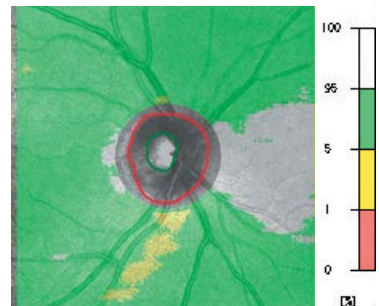
Analysis charts



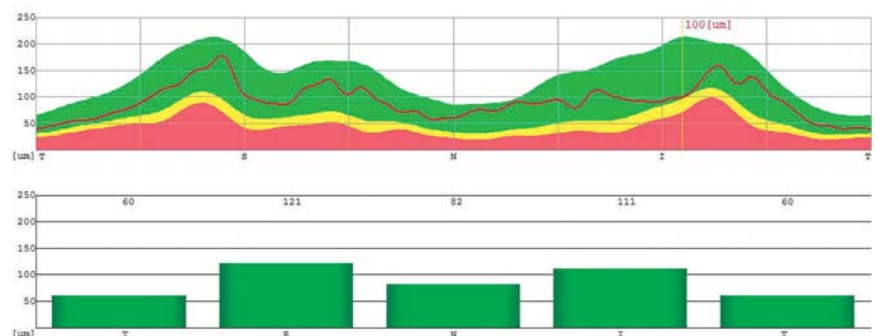
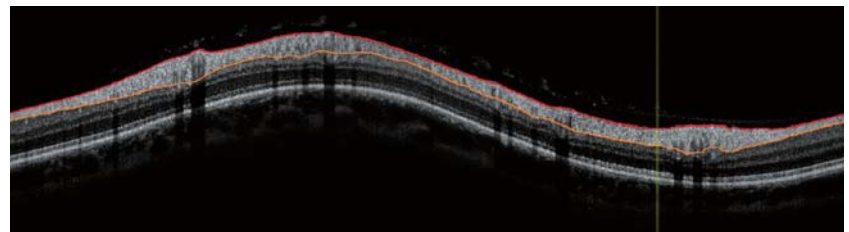
NDB/ [NFL+GCL+IPL]  
thickness map



NDB/ RNFL  
thickness map



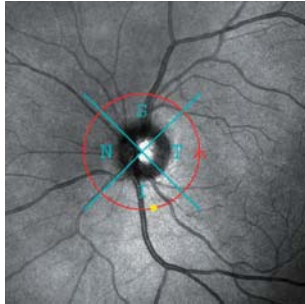
TSNIT Graph



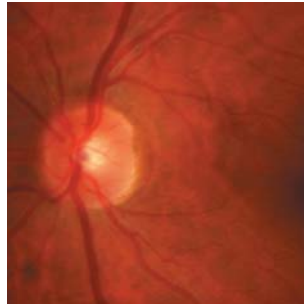
With normal mean values in the **Analysis charts**:  
The **NDB/[NFL+GCL+IPL] thickness map** shows thinner locations in the lower area. **NDB of RNFL thickness map** and **TSNIT Graph** show mild nerve fiber thinning to inferior.

<Glaucoma, stage 1 acc. to Aulhorn>  
Left Eye, BCVA 20/20

SLO

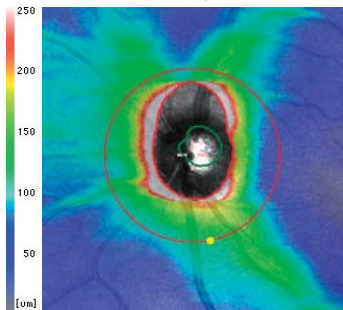


Fundus Photo

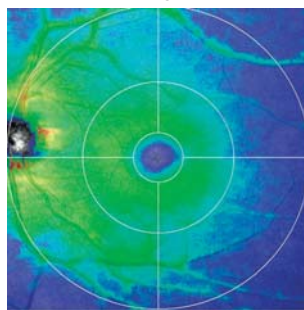


Same patient, similar findings as in the right eye

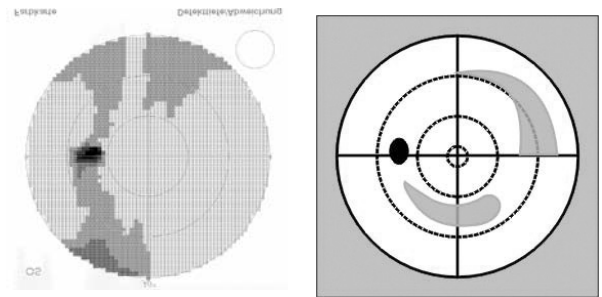
RNFL thickness map



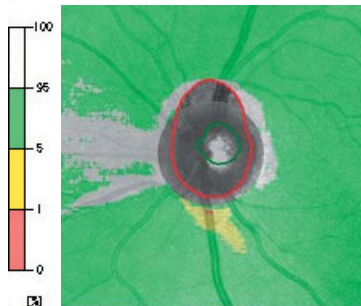
[NFL+GCL+IPL] thickness map



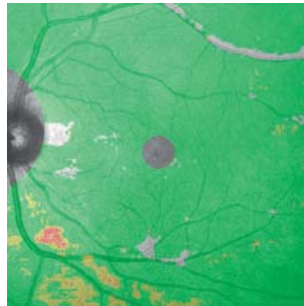
Perimeter Mirrored representation



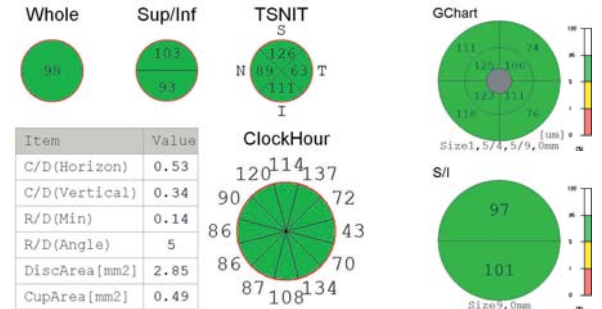
NDB/ RNFL thickness map



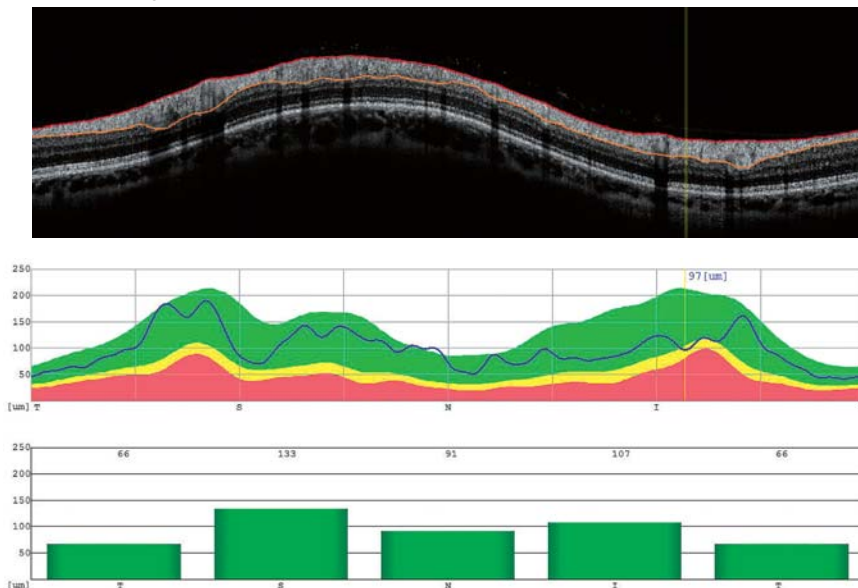
NDB/ [NFL+GCL+IPL] thickness map



Analysis charts



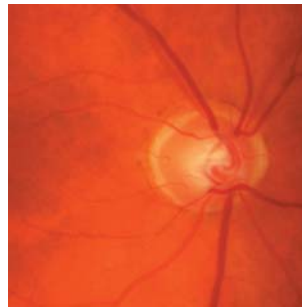
TSNIT Graph



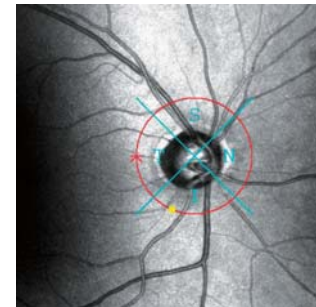
Similar findings as in the right eye

Primary open angle glaucoma, POAG, tension regulated with medication, visual fields with persistent relative and absolute scotomas in the peripheral area of the nerve fiber bundles

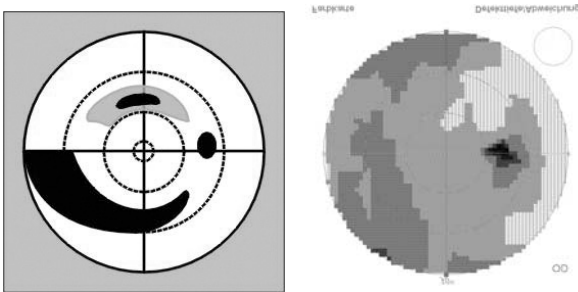
Fundus Photo



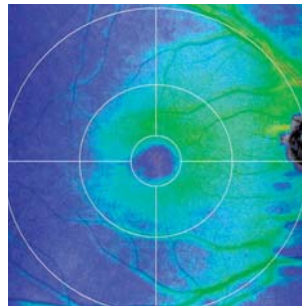
SLO



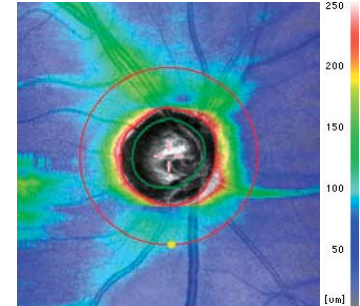
Perimeter  
Mirrored representation



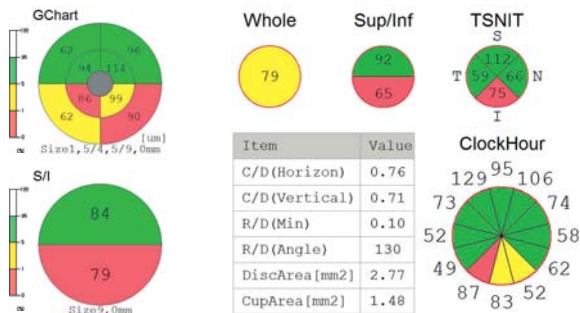
[NFL+GCL+IPL]  
thickness map



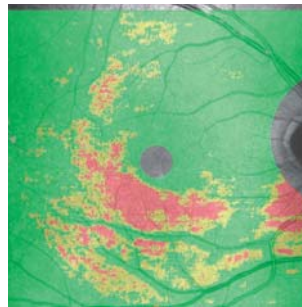
RNFL  
thickness map



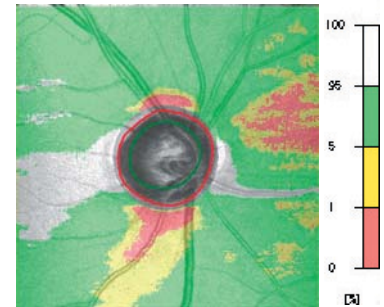
Analysis charts



NDB/ [NFL+GCL+IPL]  
thickness map

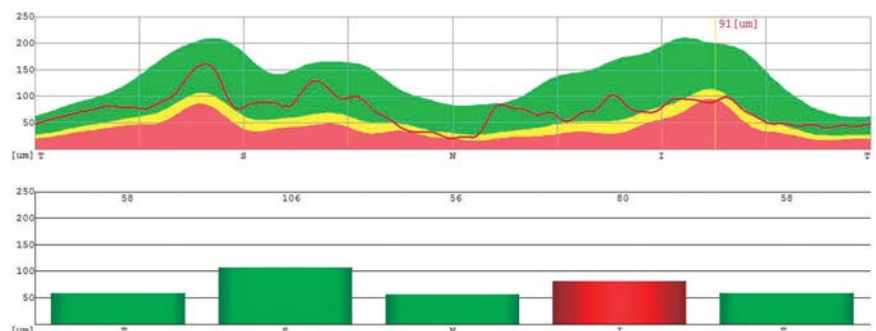
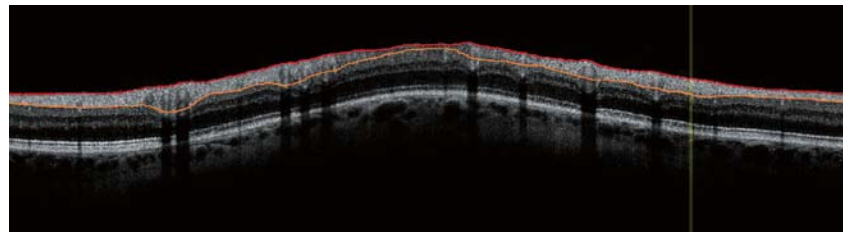


NDB/ RNFL  
thickness map

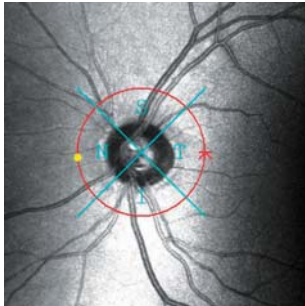


Clear sectorial loss of nerve fiber layer downwards in the **Analysis charts**, in the **[NFL+GCL+IPL]**, **NDB/[NFL+GCL+IPL]** and **NDB/RNFL thickness maps**.  
The **TSNIT graph** shows the overall and the especially clear inferior loss of nerve fiber layers.

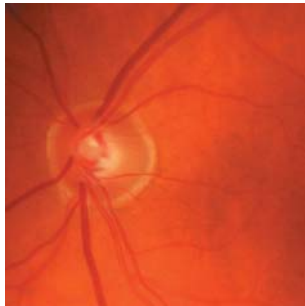TSNIT Graph



SLO

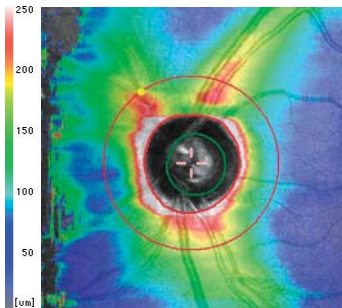


Fundus Photo

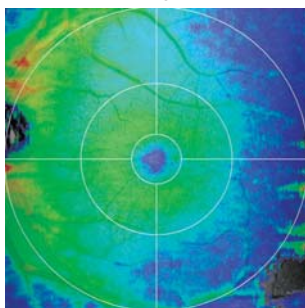


Same patient, visual field of left eye with persistent relative scotomas can be seen in the upper temporal area.

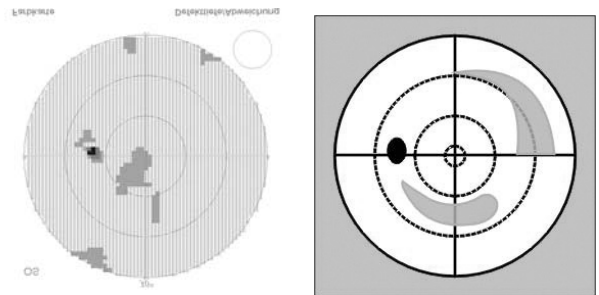
RNFL thickness map




[NFL+GCL+IPL] thickness map




Perimeter Mirrored representation



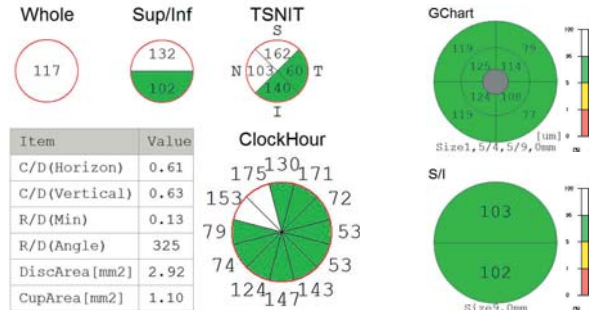
NDB/ RNFL thickness map



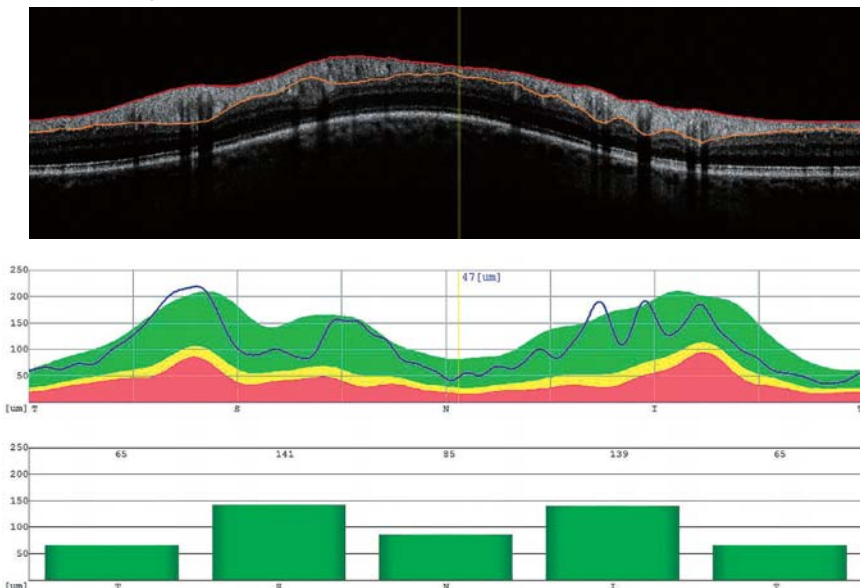
NDB/ [NFL+GCL+IPL] thickness map



Analysis charts



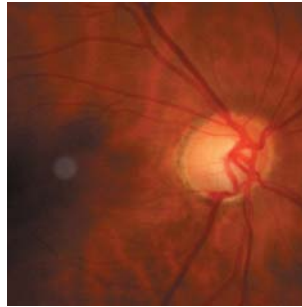
TSNIT Graph



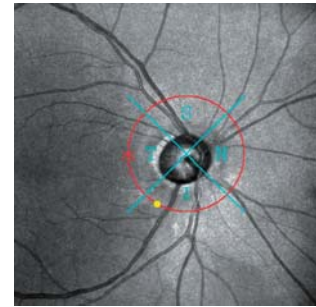
With normal mean values in the **Analysis charts** and the **NDB/RNFL thickness map**:  
The **NDB/[NFL+GCL+IPL]** shows thinned locations in the lower and peripheral area.  
The **TSNIT graph** shows early thinning in the inferior and nasal quadrants.

Normal pressure glaucoma, hypertension, blood pressure dips, tension treated with medication, optic disc excavation close to the rim downwards in both eyes, hemorrhage on the rim, sectorial, mostly superior visual field losses

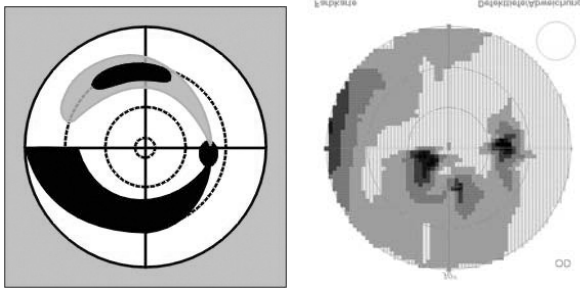
Fundus Photo



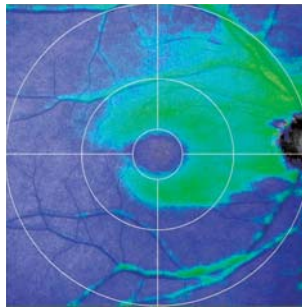
SLO



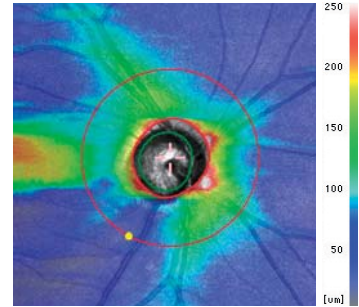
Perimeter  
Mirrored representation



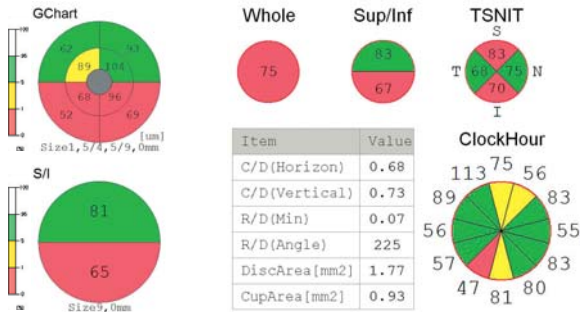[NFL+GCL+IPL]  
thickness map



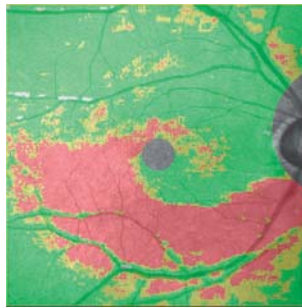
RNFL  
thickness map



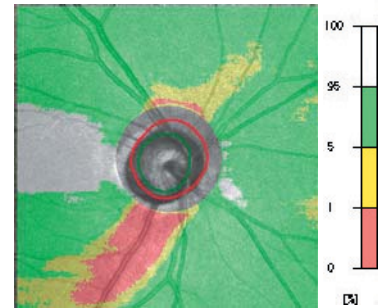
Analysis charts



NDB/ [NFL+GCL+IPL]  
thickness map

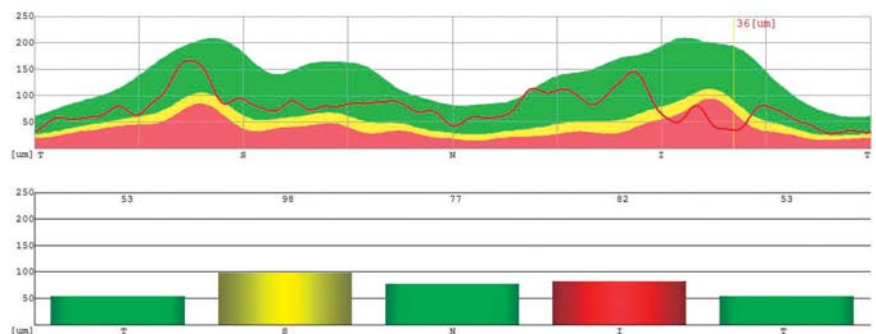
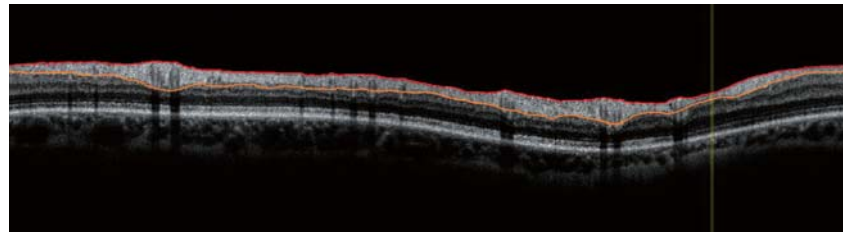


NDB/ RNFL  
thickness map



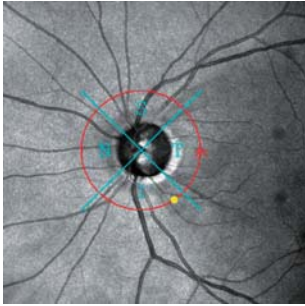
Massive sectorial losses of nerve fiber layer downwards in the **Analysis charts**, **[NFL+GCL+IPL]**, **NDB/[NFL+GCL+IPL]** and **NDB/RNFL** thickness maps. The **TSNIT graph** shows apart of the inferior also the superior loss of nerve fibers.

TSNIT Graph

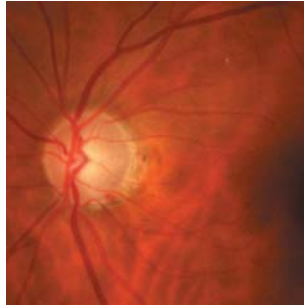




SLO

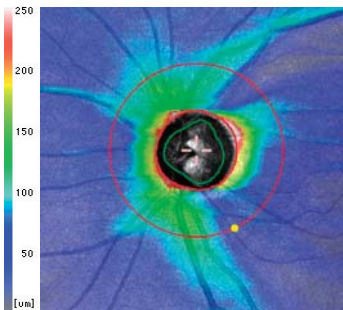


Fundus Photo

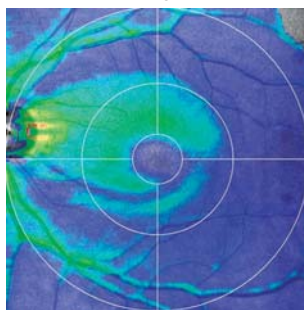


Same patient, similar results as in right eye, scotomas extended to periphery

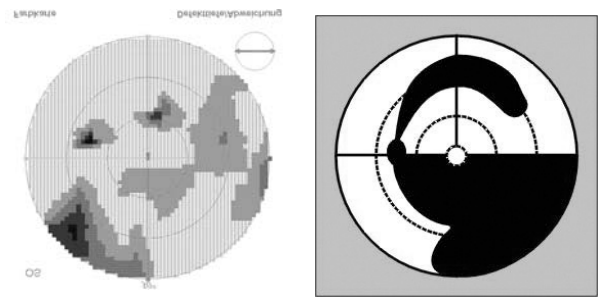
RNFL thickness map



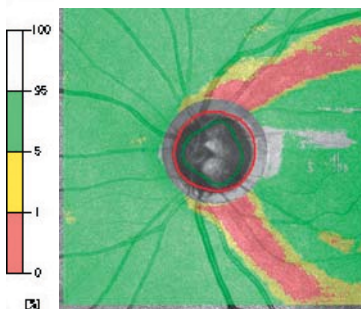
[NFL+GCL+IPL] thickness map



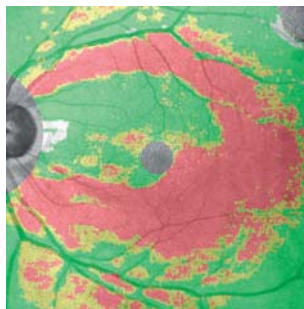
Perimeter Mirrored representation



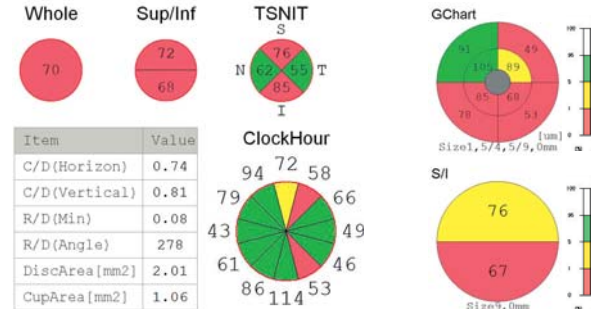
NDB/ RNFL thickness map



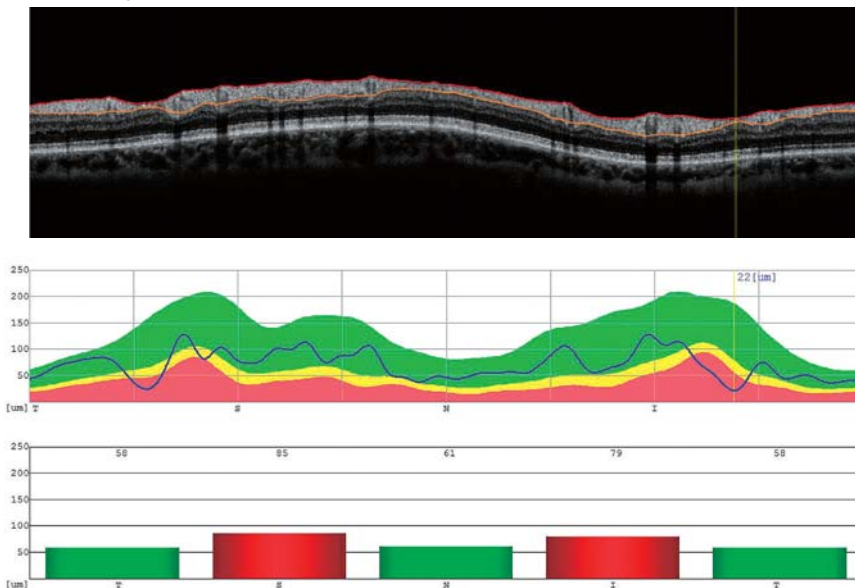
NDB/ [NFL+GCL+IPL] thickness map



Analysis charts



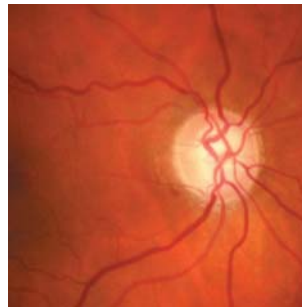
TSNIT Graph



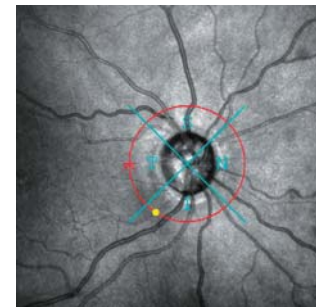
The [NFL+GCL+IPL] thickness map shows clearly the single narrow nerve fiber defects, recognizable in the TSNIT graph as narrowly confined notches.

Primary open-angle glaucoma, POAG, diabetes, hypertension, glaucoma surgery in both eyes, tension regulated with medication, loss of visual field of right eye in sectors

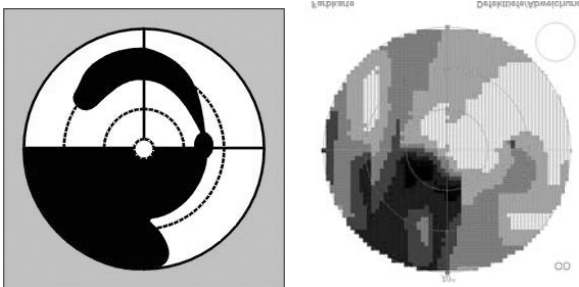
Fundus Photo



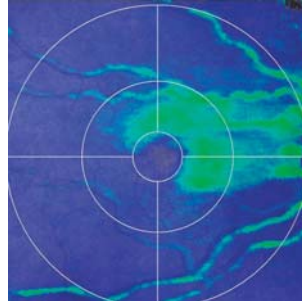
SLO



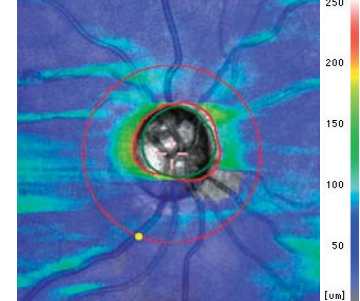
Perimeter  
Mirrored representation



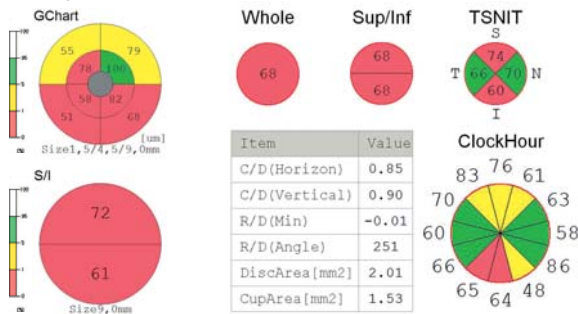
[NFL+GCL+IPL]  
thickness map




RNFL  
thickness map



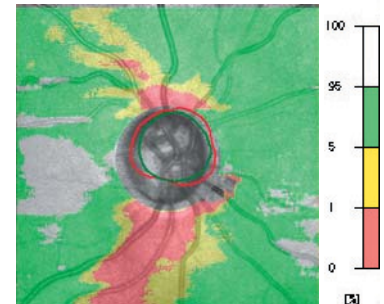
Analysis charts



NDB/ [NFL+GCL+IPL]  
thickness map



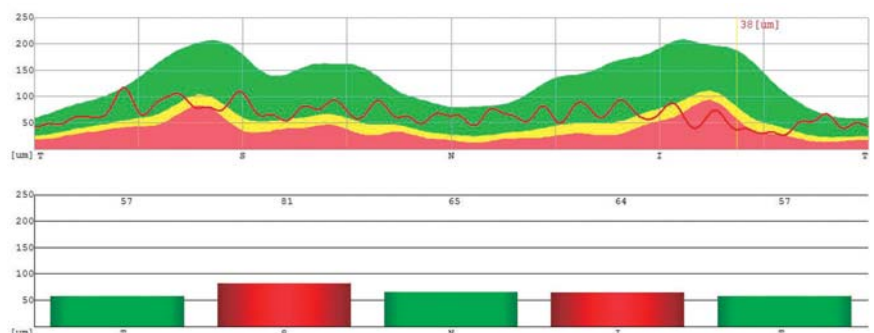
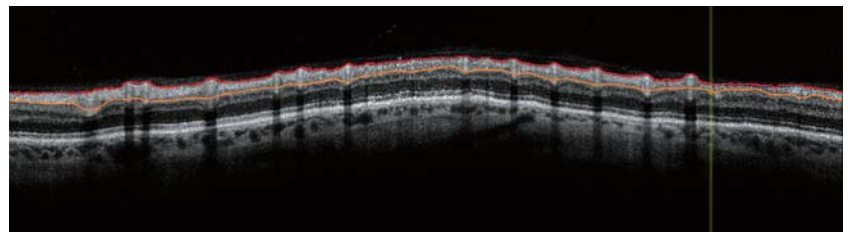
NDB/ RNFL  
thickness map



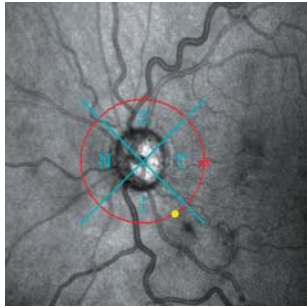
TSNIT Graph

Clear sectorial loss of nerve fiber layer with well recognizable central rest can be seen in the [NFL+GCL+IPL], NDB/[NFL+GCL+IPL] and NDB/RNFL thickness maps.

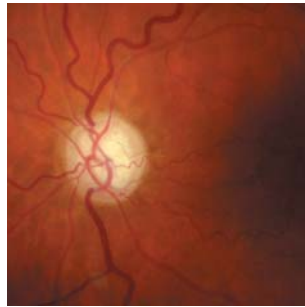The TSNIT graph show no inferior or superior peaks. The exposed retinal vessels resemble a string of pearls.



SLO

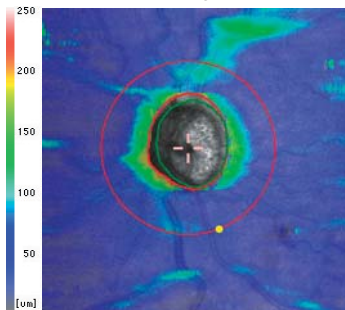


Fundus Photo




Same patient, left eye with extensive visual field losses, a small central island of vision and paracentral remnants

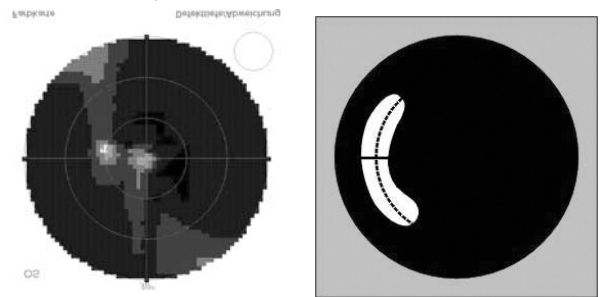
RNFL thickness map




[NFL+GCL+IPL] thickness map



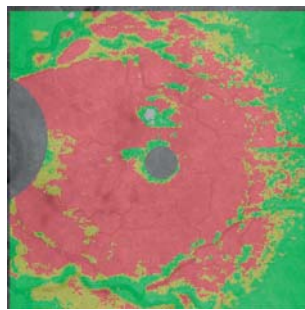
Perimeter Mirrored representation



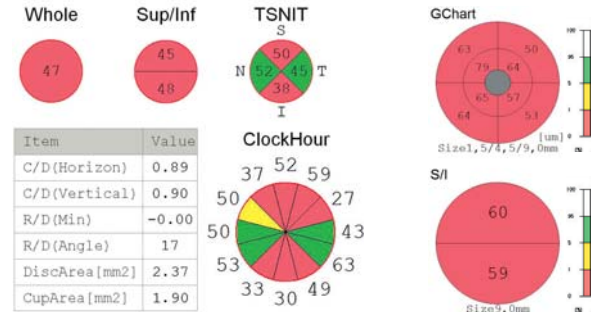
NDB/ RNFL thickness map



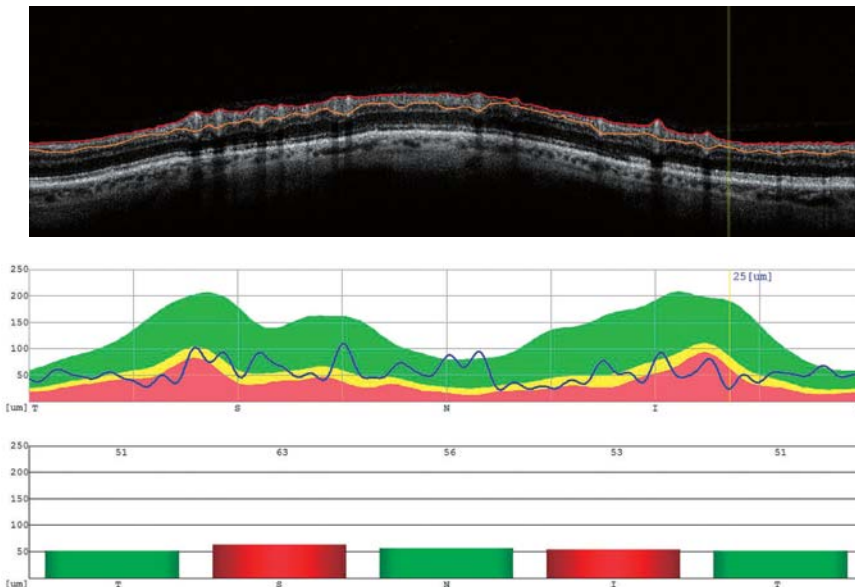
NDB/ [NFL+GCL+IPL] thickness map



Analysis charts



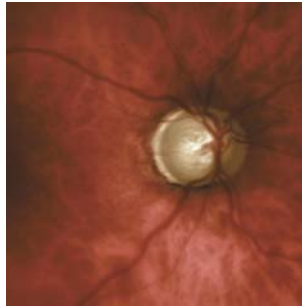
TSNIT Graph



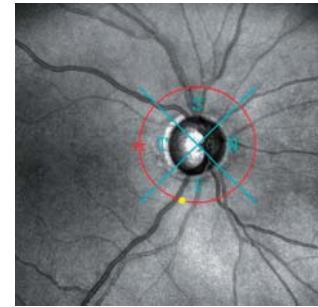
Clear loss of nerve fiber layer with small central remnants in the [NFL+GCL+IPL] thickness map. RNFL thickness map, NDB/[NFL+GCL+IPL] and NDB/RNFL thickness map as well as TSNIT Graph show the overestimated nasal and temporal remainings.

PEX Glaucoma, IOL and glaucoma surgery in right eye, tension regulated with medication, extensive visual field losses with a small central island of vision and temporal remnants

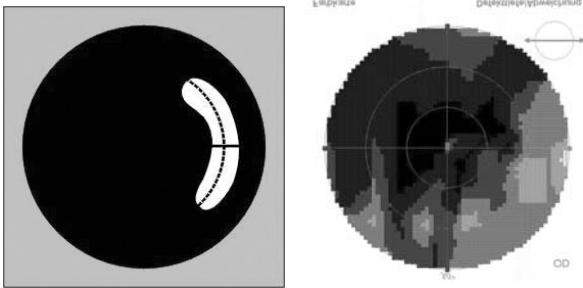
Fundus Photo




SLO



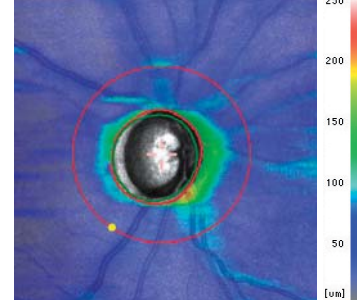
Perimeter  
Mirrored representation



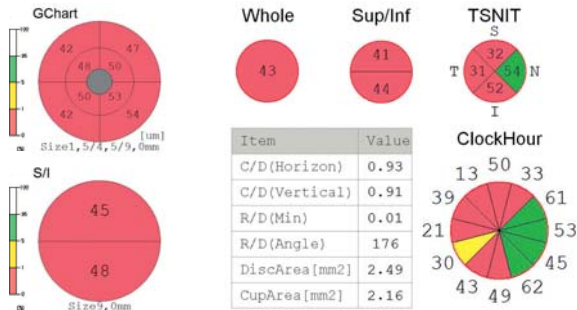[NFL+GCL+IPL]  
thickness map



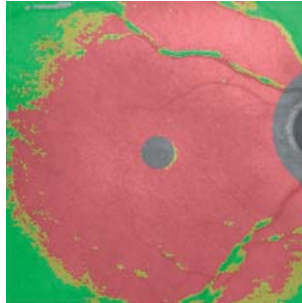
RNFL  
thickness map



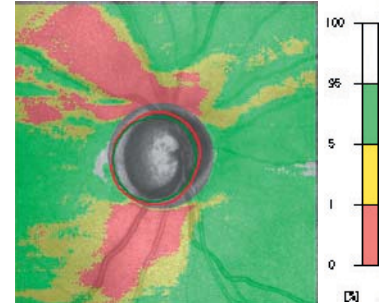
Analysis charts



NDB/ [NFL+GCL+IPL]  
thickness map



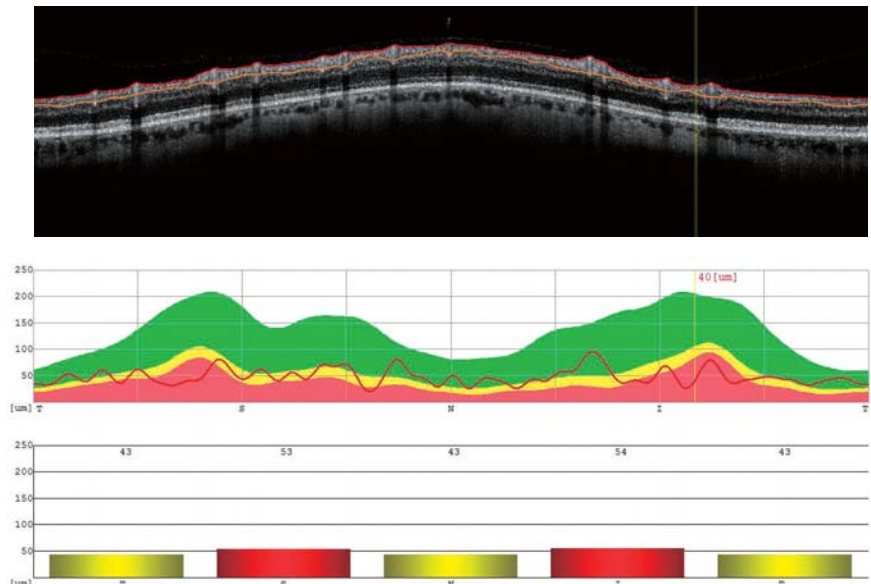
NDB/ RNFL  
thickness map



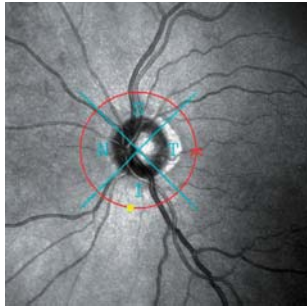
Clear losses of nerve fiber layer in the [NFL+GCL+IPL], RNFL and NDB/[NFL+GCL+IPL] thickness maps.

Recognizable nasal and temporal remnants are in the NDB/RNFL thickness map and in the TSNIT graph. In the latter the obvious exposure of retinal vessels resembling a string of pear can be noticed.

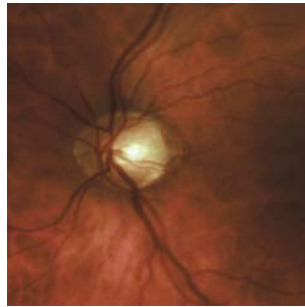
TSNIT Graph



SLO

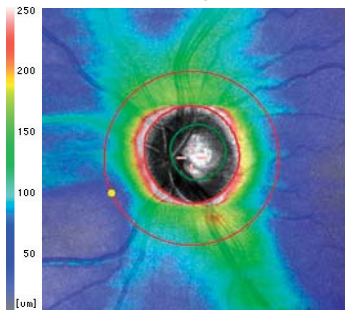


Fundus Photo

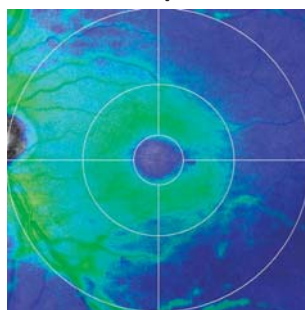


Same patient, PEX glaucoma, cataract, visual fields with persistent relative losses in the region of nerve fiber bundles

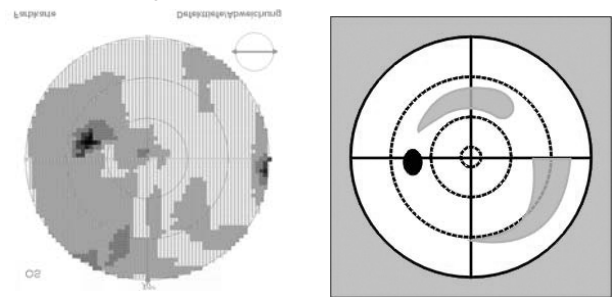
RNFL thickness map



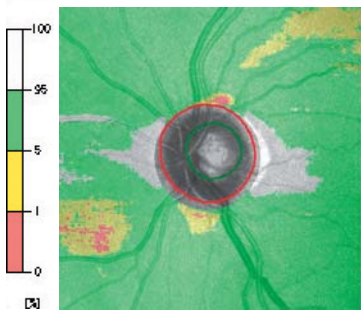
[NFL+GCL+IPL] thickness map



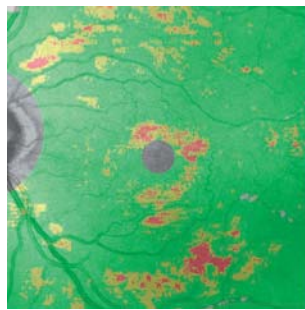
Perimeter Mirrored representation



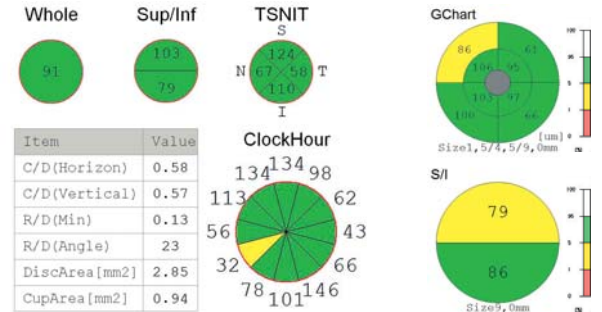
NDB/ RNFL thickness map



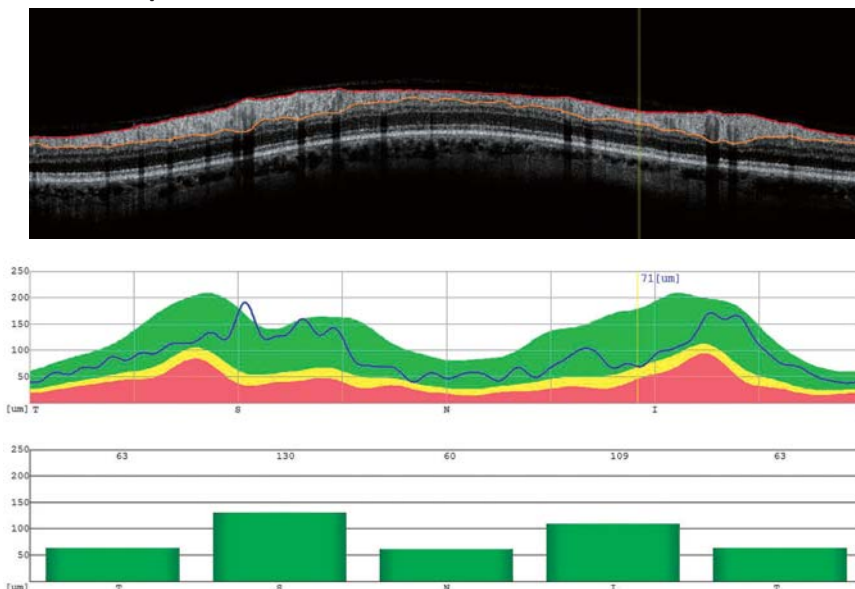
NDB/ [NFL+GCL+IPL] thickness map



Analysis charts



TSNIT Graph



With almost normal mean values in the **Analysis charts**:

The **NDB/[NFL+GCL+IPL] thickness map** shows thinned locations.

The **NDB/RNFL thickness map** and the **TSNIT graph** show mild thinning of nerve fibers, mostly in the nasal area.

## AUTHOR



**Dr. med. Heike Krueger  
Bruende, Germany**

Studies at the Philipps University in Marburg, the Academic Hospital in Fulda and the Medical School of Hannover.

Doctoral degree obtained at the Medical School of Hannover.

Specialization in ophthalmology at the Eye Clinic of the Medical School of Hannover (Director: Prof. Dr. H. Honegger)

Since 1983 active in a private eye clinic, since 1985 together with Dr. med. Cesary J. Krueger.

Affiliation:

**MuM** – Physician Network Medicine and More (Medizin und Mehr)

**BVA** – Professional Organisation of Eye Doctors (Berufsverband der Augenärzte)

**RWA** – Association of Eye Doctors of Rheinland-Westphalia (Verein Rheinisch-Westfälischer Augenärzte)

**DAKG** – German Contact Lense Society of Eye Doctors (Deutsche augenärztliche Kontaktlinsengesellschaft)

[www.augenaerzte-krueger.de](http://www.augenaerzte-krueger.de)  
[www.oct-bilder.de](http://www.oct-bilder.de)



**Dr. med. Cesary J. Krueger  
Bruende, Germany**

Studies at the Philipps University in Marburg, the Academic Hospital in Fulda and the Medical School of Hannover.

Doctoral degree obtained at the Medical School of Hannover.

Researcher in the Department for Experimental Ophthalmology of the Max-Planck Institute for Physiological and Clinical Research, Bad Nauheim (Director: Prof. Dr. E. Dodt) in association with the University Eye Clinic Frankfurt (Director: Prof. Dr. W. Doden)

Specialization in ophthalmology at the Eye Clinic of the Medical School of Hannover (Director: Prof. Dr. H. Honegger)

Affiliation:

**MuM** – Physician Network Medicine and More (Medizin und Mehr)

**BVA** – Professional Organisation of Eye Doctors (Berufsverband der Augenärzte)

**RWA** – Association of Eye Doctors of Rheinland-Westphalia (Verein Rheinisch-Westfälischer Augenärzte)

**DOG** – German Ophthalmological Society (Deutsche ophthalmologische Gesellschaft)

**DAKG** – German Contact Lense Society of Eye Doctors (Deutsche augenärztliche Kontaktlinsengesellschaft)





Eye & Health Care

**NIDEK CO., LTD**